

# ACR–ACOG–AIUM–SMFM–SRU PRACTICE PARAMETER FOR THE PERFORMANCE OF STANDARD DIAGNOSTIC OBSTETRICAL ULTRASOUND

The American College of Radiology, with more than 40,000 members, is the principal organization of radiologists, radiation oncologists, and clinical medical physicists in the United States. The College is a nonprofit professional society whose primary purposes are to advance the science of radiology, improve radiologic services to the patient, study the socioeconomic aspects of the practice of radiology, and encourage continuing education for radiologists, radiation oncologists, medical physicists, and persons practicing in allied professional fields.

The American College of Radiology will periodically define new practice parameters and technical standards for radiologic practice to help advance the science of radiology and to improve the quality of service to patients throughout the United States. Existing practice parameters and technical standards will be reviewed for revision or renewal, as appropriate, on their fifth anniversary or sooner, if indicated.

Each practice parameter and technical standard, representing a policy statement by the College, has undergone a thorough consensus process in which it has been subjected to extensive review and approval. The practice parameters and technical standards recognize that the safe and effective use of diagnostic and therapeutic radiology requires specific training, skills, and techniques, as described in each document. Reproduction or modification of the published practice parameter and technical standard by those entities not providing these services is not authorized.

## PREAMBLE

This document is an educational tool designed to assist practitioners in providing appropriate radiologic care for patients. Practice Parameters and Technical Standards are not inflexible rules or requirements of practice and are not intended, nor should they be used, to establish a legal standard of care<sup>1</sup>. For these reasons and those set forth below, the American College of Radiology and our collaborating medical specialty societies caution against the use of these documents in litigation in which the clinical decisions of a practitioner are called into question.

The ultimate judgment regarding the propriety of any specific procedure or course of action must be made by the practitioner considering all the circumstances presented. Thus, an approach that differs from the guidance in this document, standing alone, does not necessarily imply that the approach was below the standard of care. To the contrary, a conscientious practitioner may responsibly adopt a course of action different from that set forth in this document when, in the reasonable judgment of the practitioner, such course of action is indicated by variables such as the condition of the patient, limitations of available resources, or advances in knowledge or technology after publication of this document. However, a practitioner who employs an approach substantially different from the guidance in this document may consider documenting in the patient record information sufficient to explain the approach taken.

The practice of medicine involves the science, and the art of dealing with the prevention, diagnosis, alleviation, and treatment of disease. The variety and complexity of human conditions make it impossible to always reach the most appropriate diagnosis or to predict with certainty a particular response to treatment. Therefore, it should be recognized that adherence to the guidance in this document will not assure an accurate diagnosis or a successful outcome. All that should be expected is that the practitioner will follow a reasonable course of action based on current knowledge, available resources, and the needs of the patient to deliver effective and safe medical care. The purpose of this document is to assist practitioners in achieving this objective.

---

<sup>1</sup> *Iowa Medical Society and Iowa Society of Anesthesiologists v. Iowa Board of Nursing*, 831 N.W.2d 826 (Iowa 2013) Iowa Supreme Court refuses to find that the "ACR Technical Standard for Management of the Use of Radiation in Fluoroscopic Procedures (Revised 2008)" sets a national standard for who may perform fluoroscopic procedures in light of the standard's stated purpose that ACR standards are educational tools and not intended to establish a legal standard of care. See also, *Stanley v. McCarver*, 63 P.3d 1076 (Ariz. App. 2003) where in a concurring opinion the Court stated that "published standards or guidelines of specialty medical organizations are useful in determining the duty owed or the standard of care applicable in a given situation" even though ACR standards themselves do not establish the standard of care.

## I. INTRODUCTION

The clinical aspects contained in specific sections of this practice parameter (Introduction, Classification of Fetal Ultrasound Examinations, Specifications of the Examination, Equipment Specifications, and Fetal Safety) were revised collaboratively by the American College of Radiology (ACR), the American Institute of Ultrasound in Medicine (AIUM), the American College of Obstetricians and Gynecologists (ACOG), the Society for Maternal Fetal Medicine (SMFM), and the Society of Radiologists in Ultrasound (SRU). Recommendations for Qualifications and Responsibilities of Personnel, Written Request for the Examination, Documentation, and Quality Control and Improvement, Safety, Infection Control, and Patient Education vary among the organizations and are addressed by each separately.

Obstetrical ultrasound <sup>2</sup> should be performed only when there is a valid medical reason, and the lowest possible acoustic output settings should be used to gain the necessary diagnostic information [1-3].

Although this practice parameter describes the key elements of standard ultrasound examinations in the first, second, and third trimesters of pregnancy, a more detailed fetal anatomic examination may be necessary in some cases, such as when an abnormality is found or suspected on the standard examination or in pregnancies at high risk for fetal anomaly [4]. In some cases, other imaging may be necessary as well.

Although it is not possible to detect all structural congenital anomalies with diagnostic ultrasound, adherence to the following practice parameters will increase the likelihood of detecting many fetal abnormalities.

---

<sup>2</sup> The consensus of the committee was that the use of the terms "ultrasound" or "sonography" is at the discretion of each organization.

## II. CLASSIFICATION OF FETAL ULTRASOUND EXAMINATIONS

### A. Standard First Trimester Ultrasound Examination

A standard obstetrical ultrasound examination in the first trimester includes evaluation of the presence, size, location, and number of gestational sac(s). The gestational sac is examined for the presence of yolk sac and embryo/fetus (a fetus is generally defined as greater than or equal to 10 weeks' gestational age) [5]. When an embryo/fetus is detected, the crown rump length should be measured, and the presence or absence of cardiac activity should be recorded by cine clip or M-mode. The routine use of pulsed Doppler ultrasound to either document or "listen" to embryonic/fetal cardiac activity is discouraged [6]. The uterus, cervix, adnexa, and cul-de-sac region should be examined.

## II. CLASSIFICATION OF FETAL ULTRASOUND EXAMINATIONS

### B. Standard Second or Third Trimester Ultrasound Examination

An obstetrical ultrasound in the second or third trimester includes an evaluation of fetal number, cardiac activity, presentation, amniotic fluid volume, placental position, placental cord insertion site, fetal biometry, anatomic survey, and growth. The patient's cervix, uterus, and adnexa should be examined.

## II. CLASSIFICATION OF FETAL ULTRASOUND EXAMINATIONS

### C. Limited Ultrasound Examination

A limited obstetric ultrasound examination is performed to answer a specific, acute clinical question when an immediate impact on management is anticipated and when time or other constraints make performance of a standard ultrasound impractical or unnecessary. If a limited obstetric ultrasound is performed on a patient who has not previously had a standard or detailed ultrasound examination, a subsequent standard or detailed

ultrasound should be obtained where appropriate. In patients who require serial ultrasounds and have already had a standard or detailed scan, some will only need limited scans, whereas others will require standard or detailed follow-up examinations. Clinical judgement should be used to determine the proper type of ultrasound examination to perform and the appropriate frequency for follow-up ultrasound examinations [7].

## II. CLASSIFICATION OF FETAL ULTRASOUND EXAMINATIONS

### D. Specialized Ultrasound Examination

A detailed anatomic examination is performed for patients at risk for fetal anatomic or karyotypic abnormalities (including, but not limited to, advanced patient age, medical complications of pregnancy, or pregnancy after assisted reproductive technology) or when an anomaly is suspected on the basis of history, abnormal biochemical markers, cell-free DNA screening, or the results of either the limited or standard scan [4].

Other specialized ultrasound scans may include fetal echocardiogram, biophysical profile and fetal Doppler ultrasound, or additional biometric measurements including nuchal translucency (NT) and cervical length [8-14].

## III. QUALIFICATIONS AND RESPONSIBILITIES OF PERSONNEL

See the [ACR–SPR–SRU Practice Parameter For The Performance And Interpretation of Diagnostic Ultrasound Examinations](#) [15].

## IV. SPECIFICATIONS OF THE EXAMINATION

The written or electronic request for an obstetrical ultrasound examination should provide sufficient information to demonstrate the medical necessity of the examination and allow for its proper performance and interpretation.

Documentation that satisfies medical necessity includes 1) signs and symptoms and/or 2) relevant history (including known diagnoses). Additional information regarding the specific reason for the examination or a provisional diagnosis would be helpful and may at times be needed to allow for the proper performance and interpretation of the examination.

The request for the examination must be originated by a physician or other appropriately licensed health care provider. The accompanying clinical information should be provided by a physician or other appropriately licensed health care provider familiar with the patient's clinical problem or question and consistent with the state's scope of practice requirements. (ACR Resolution 35 adopted in 2006 – revised in 2016, Resolution 12-b)

## IV. SPECIFICATIONS OF THE EXAMINATION

### A. Standard First Trimester Ultrasound Examination

#### 1. Indications for first trimester [3]ultrasound examinations include, but are not limited to:

- a. Confirmation of the presence of an intrauterine pregnancy [16-18]
- b. Confirmation of cardiac activity [19-23]
- c. Estimation of gestational age [24-26]
- d. Diagnosis or evaluation of multiple gestations including determination of chorionicity and amnionicity [27,28]
- e. Evaluation of a suspected ectopic or abnormally implanted pregnancy [29,30]
- f. Evaluating the cause of vaginal bleeding
- g. Evaluation of pelvic pain
- h. Evaluation of suspected gestational trophoblastic disease [31]
- i. Measuring the NT and nasal bone when part of a screening program for fetal aneuploidy
- j. Assessing for fetal anomalies detectable in the first trimester, such as anencephaly [9,10,32-40]
- k. Imaging as an adjunct to chorionic villus sampling, embryo transfer, and localization and removal of an

intrauterine device

I. Evaluation of pelvic masses and/or uterine abnormalities

---

<sup>3</sup>For the purpose of this document, first trimester represents 1w-13w + 6d.

#### IV. SPECIFICATIONS OF THE EXAMINATION

##### A. Standard First Trimester Ultrasound Examination

##### 2. Imaging parameters

Scanning in the first trimester may be performed transabdominally, transvaginally, or a combination of both. If a transabdominal examination is not definitive, a transvaginal scan is recommended

- a. The uterus (including the cervix) and adnexa should be evaluated for the presence of a gestational sac. If a gestational sac is seen, the location, size, and shape should be documented. The gestational sac should be evaluated for the presence or absence of a yolk sac and embryo/fetus. If an embryo/fetus is identified, the crown-rump length should be measured[17,24-26,41].

A definitive diagnosis of intrauterine pregnancy can be made when an intrauterine gestational sac containing a yolk sac or embryo/fetus with or without cardiac activity is visualized. In a very early intrauterine pregnancy, a small, eccentric intrauterine fluid collection with an echogenic rim can be seen before the yolk sac and embryo. In the absence of sonographic signs of ectopic pregnancy, the fluid collection is highly likely to represent an intrauterine gestational sac. Follow-up ultrasound and/or serial determination of patient serum beta– human chorionic gonadotropin levels are appropriate in pregnancies of undetermined location to avoid inappropriate intervention in a potentially viable early pregnancy [16,20,21].

Caution should be used in making the presumptive diagnosis of a gestational sac in the absence of a definite yolk sac or embryo. If the embryo is not identified, the mean sac diameter may be useful for determining the timing of ultrasound follow-up. However, the crown-rump length is a more accurate indicator of gestational age than the mean gestational sac diameter.

- b. The presence or absence of cardiac activity should be documented with a cine clip or M-mode [6].

With transvaginal scans, cardiac motion is usually observed when the embryo is 2 mm or greater in length; if an embryo less than 7 mm in length is seen without cardiac activity, a subsequent scan in one week is recommended to ensure that the pregnancy is nonviable [19-23].

- c. Fetal number should be documented.

Amnionicity and chorionicity should be documented for all multiple gestations [27].

- d. In the later first trimester, fetal anatomy should be assessed and include the cranium, midline falx, choroid plexus, profile including nasal bone, lungs, stomach, situs, abdominal umbilical cord insertion, and the presence of limbs. A four-chamber view should be evaluated if technically feasible. [32-36,42-44].

- e. The nuchal region should be imaged, and abnormalities such as cystic hygroma should be documented.

A precise NT measurements should be obtained in these scenarios:

1. If a measurement is required as part of aneuploidy risk calculation (in conjunction with serum analytes). In this setting, it is important that the practitioner measure the NT according to established guidelines. A quality assessment program is recommended to ensure that false-positive and false-negative results are kept to a minimum [9,10].
2. If the NT appears subjectively enlarged. In practices in which cell-free DNA is used primarily for aneuploidy screening, an enlarged NT may be considered a sonographic marker of structural, genetic, or syndromic abnormalities.

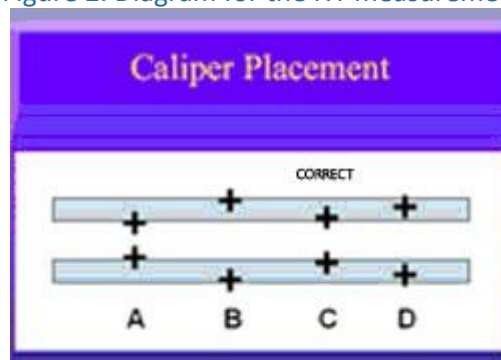
Guidelines for NT measurement:

- i. The margins of the NT edges must be clear with the angle of insonation perpendicular to the NT line.
- ii. The fetus must be in the midsagittal plane. The tip of the nose, palate, and diencephalon should be seen.
- iii. The image must be magnified so that it is filled by the fetal head, neck, and upper thorax.
- iv. The fetal neck must be in a neutral position, with the head in line with the spine, not flexed and not hyperextended.
- v. The amnion must be seen as separate from the NT line.
- vi. The (+) calipers on the ultrasound must be used to perform the NT measurement.
- vii. Electronic calipers must be placed on the inner borders of the nuchal line with none of the horizontal crossbar itself protruding into the space.
- viii. The calipers must be placed perpendicular to the long axis of the fetus.
- ix. The measurement must be obtained at the widest space of the NT.

Figure 1. Ultrasound image of NT measurement

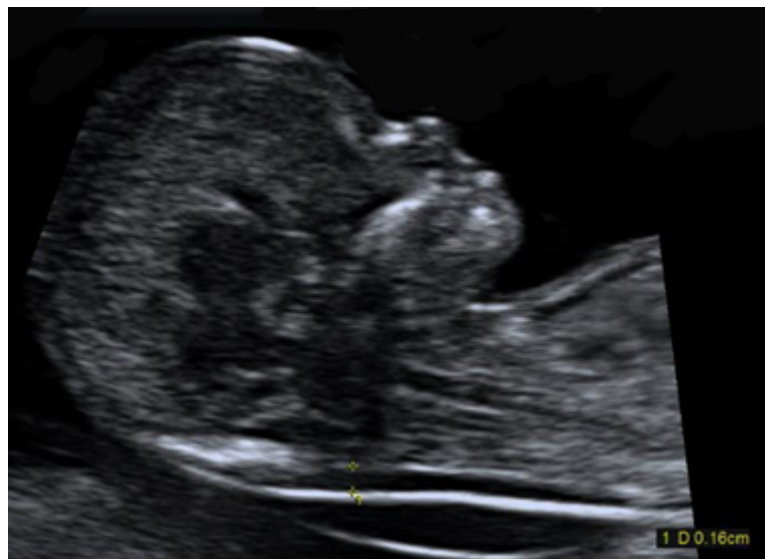

Figure 2. Diagram for the NT measurement



- f. The uterus, including the cervix, adnexal structures, and cul-de-sac, should be evaluated. Abnormalities should be imaged and documented.

The presence, location, appearance, and size of adnexal masses should be documented. The presence and number of leiomyomata should be documented. The measurements of the largest or any potentially clinically significant leiomyomata should be documented. The cul-de-sac should be evaluated for the presence or absence of fluid. Uterine anomalies should be documented.

#### **IV. SPECIFICATIONS OF THE EXAMINATION**

##### **B. Standard Second and Third Trimester Ultrasound Examination [17]**

1. These examinations are commonly performed to assess fetal anatomy and biometry. Other indications include but are not limited to:
  - a. Screening for fetal anomalies [49-54]
  - b. Evaluation of fetal anatomy [55-64]
  - c. Estimation of gestational age [49]
  - d. Evaluation of suspected multiple gestation
  - e. Evaluation of cervical length [11-13,65-69]
  - f. Evaluation of fetal growth [70-73]
  - g. Evaluation of significant discrepancy between uterine size and clinical dates
  - h. Determination of fetal presentation
  - i. Evaluation of fetal well-being [43]
  - j. Suspected amniotic fluid abnormalities [74-76]
  - k. Evaluation of premature rupture of membranes and/or premature labor
  - l. Evaluation of vaginal bleeding
  - m. Evaluation of abdominal or pelvic pain
  - n. Suspected placental abruption
  - o. Suspected fetal death
  - p. Follow-up evaluation of a fetal anomaly [77]
  - q. Evaluation/follow-up of placental appearance and location. Includes suspected placenta previa, vasa previa, and evaluation of placenta accreta spectrum) [78]
  - r. Adjunct to amniocentesis or other procedure
  - s. Adjunct to external cephalic version
  - t. Evaluation of suspected gestational trophoblastic disease
  - u. Evaluation of pelvic mass
  - v. Suspected uterine anomalies

In certain clinical circumstances, a more detailed examination of fetal anatomy may be indicated [79].

2. Imaging parameters for a standard fetal examination
  - a. Fetal cardiac activity (by cine clip or M-mode), fetal number, and presentation should be documented.

Abnormal heart rate and/or rhythm should be documented.

Multiple gestations require the documentation of additional information: chorionicity, amnionicity, comparison of fetal sizes, evaluation of amniotic fluid volume in each gestational sac, and fetal genitalia (when visualized).

- b. A qualitative or semiquantitative estimate of amniotic fluid volume should be documented.

Although it is acceptable for experienced examiners to qualitatively estimate amniotic fluid volume, semiquantitative methods have also been described for this purpose (eg, amniotic fluid index [AFI], single deepest pocket, and 2-D pocket). In assessing oligohydramnios, the deepest vertical pocket (<2 cm) is preferred over AFI (=5 cm) because it results in fewer obstetrical interventions without a significant difference in perinatal outcome, and single deepest pocket should be at least 1 cm wide [74-76,80,81]. Polyhydramnios (deepest vertical pocket =8 cm or AFI =24 cm) may be associated with other pregnancy complications [80].

- c. The placental location, appearance, and relationship to the internal cervical os should be documented. In patients who have had one or more prior cesarean deliveries, a detailed evaluation of the placental location and attachment in the lower uterine segment should be performed looking for signs of placenta accreta spectrum. The umbilical cord should be imaged, and the number of vessels in the cord documented. The placental cord insertion site should be documented when technically possible [82,83].

It is recognized that apparent placental position early in pregnancy may not correlate well with its location at the time of delivery.

Transvaginal ultrasound should be performed if the relationship between the cervix and the placenta cannot be assessed.

Vasa previa, defined as fetal vessels in close proximity to the cervix (typically within 2 cm of the internal cervical os), is associated with a high risk of fetal morbidity and mortality if not diagnosed prior to labor [84-86]. Risk factors for vasa previa include resolving low-lying/placenta previa, bilobed/succenturiate lobe of the placenta, velamentous cord insertion, multiple gestations, and in vitro fertilization [87]. Transvaginal ultrasound with color and pulsed Doppler (to document fetal vessels) should be performed in scenarios in which vasa previa is suspected [88].

- d. Gestational age assessment

First-trimester crown-rump measurement is the most accurate means for sonographic dating of pregnancy. Beyond this period, a variety of sonographic parameters such as biparietal diameter, abdominal circumference, and femoral diaphysis length can be used to estimate gestational age. It should be noted that abdominal circumference is the least reliable of these measurements for estimating gestational age [89,90]. The variability of gestational age estimation, however, increases with advancing pregnancy. Significant discrepancies between gestational age and fetal measurements may suggest the possibility of a fetal growth abnormality [70-73].

Gestational age assessment by ultrasound in the early second trimester (between 14 0/7 weeks' and 21 6/7 weeks' gestation) is based on a composite of fetal biometric measurements and has an accuracy of  $\pm 7$ -10 days [91].

The pregnancy should NOT be redated after an accurate earlier scan has been performed and is available for comparison [92,93].

- i. Biparietal diameter is measured at the level of the thalami and cavum septi pellucidi [94]. The cerebellar hemispheres should not be visible in this scanning plane. The measurement is typically measured from the outer edge of the proximal skull to the inner edge of the distal skull.

The head shape may be elongated (dolichocephaly) or rounded (brachycephaly) as a normal variant. Under these circumstances, certain variants of normal fetal head development may make measurement of the head circumference more reliable than biparietal diameter for estimating gestational age.

- ii. Head circumference is measured at the same level as the biparietal diameter, around the outer perimeter of the bony calvarium, excluding subcutaneous tissues of the skull. This measurement is not affected by head shape.
- iii. Femoral diaphysis length can be reliably used after 14 weeks' gestational age. The long axis of the femoral shaft is most accurately measured with the beam of insonation being perpendicular to the shaft, excluding the distal femoral epiphysis.
- iv. Abdominal circumference or average abdominal diameter should be determined at the skin line on a true transverse view at the level of the junction of the umbilical vein, portal sinus, and fetal stomach when visible.

e. Fetal weight estimation

Fetal weight can be estimated from measurements such as the biparietal diameter, head circumference, abdominal circumference or average abdominal diameter, and femoral diaphysis length [95,96]. Results from various prediction models can be subsequently compared to fetal weight percentiles from published nomograms [70-73,97-99].

If previous studies have been performed, appropriateness of growth should also be documented. Scans for growth evaluation should be performed no more frequently than 2-week intervals. A shorter scan interval may result in confusion as to whether measurement changes are truly due to growth as opposed to technical variations [100-103].

Currently, even the best fetal weight prediction methods can yield errors as high as  $\pm 15\%$  [104].

f. Patient anatomy

Evaluation of the uterus, adnexal structures, and cervix should be performed.

The presence, location, and size of adnexal masses and the presence of at least the largest and potentially clinically significant leiomyomata should be documented. It is not always possible to image the normal ovaries during the second and third trimesters.

If the cervix appears abnormal (shortened or funneled) or is not adequately visualized during the transabdominal ultrasound, a transvaginal scan is recommended [11,12,67,105].

If a referring health provider desires a precise cervical-length measurement, a transvaginal measurement of the cervix should be performed [11,12,65-69].

A midline lower uterine segment contraction may obscure the internal os, giving the false impression of a longer endocervical canal. Excessive manual pressure with the ultrasound transducer may also falsely elongate the cervix.

Table 1. Criteria for cervical-length measurement

<u>CRITERIA</u>
Bladder empty
Transvaginal scan
Cervix occupies 75% of available image space

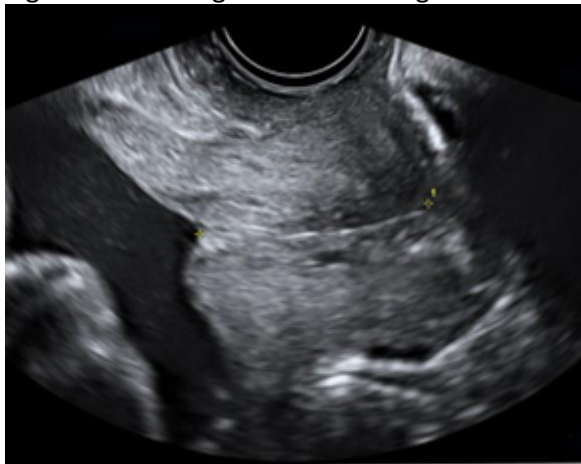

Calipers placed at the internal and external os where the anterior and posterior walls of the cervix meet. If the endocervical canal curves, two or more linear measurements may be used and added together to obtain the cervical length.

Shortest, best of 3 measurements is reported.

Dynamic cervical shortening- examination time 3 minutes and/or suprapubic/fundal pressure.

Figure 3. Transvaginal cervical-length measurement



g. Fetal anatomic survey

Fetal anatomy, as described in this document, may be adequately assessed by ultrasound after approximately 18 weeks gestational age . It may be possible to document normal structures before this time, although some structures can be difficult to visualize because of fetal size, position, movement, abdominal scars, or increased patient body mass index [106-109]. A second or third trimester scan may pose technical limitations for an anatomic evaluation due to imaging artifacts from acoustic shadowing. When this occurs, the report of the ultrasound examination should document the nature of this technical limitation. A follow-up examination may be helpful.

The following areas of assessment represent the minimal elements of a standard examination of fetal anatomy. A more detailed fetal anatomic examination may be necessary if an abnormality or suspected abnormality is found on the standard examination.

- i. Head, face, and neck
  - Lateral cerebral ventricles
  - Choroid plexus
  - Midline falx
  - Cavum septi pellucidi
  - Cerebellum
  - Cisterna magna
  - Upper lip
  - Profile (including nasal bone)

A measurement of the nuchal fold may be helpful during a specific age interval (approximately 16-20 weeks gestational age) to assess the risk of aneuploidy [110].

- ii. Chest
  - Heart [111]

- Four-chamber view
- Heart size, position, and situs
- Left ventricular outflow tract
- Right ventricular outflow tract
- Three-vessel view and three-vessel trachea view, if technically feasible [59-64]
- iii. Abdomen
  - Stomach (presence, size, and situs)
  - Bowel
  - Kidneys
  - Urinary bladder
  - Umbilical cord insertion site into the fetal abdomen
  - Umbilical cord vessel number
- iv. Spine
  - Cervical, thoracic, lumbar, and sacral spine
- v. Extremities
  - Presence of legs and arms
  - Presence of hands and feet
- vi. External Genitalia
  - If medically indicated or the patient wants to know

## V. DOCUMENTATION

Reporting should be in accordance with the [ACR Practice Parameter for Communication of Diagnostic Imaging Findings \[96\]](#).

Adequate documentation of the study is essential for high-quality patient care. There should be a permanent record of the ultrasound examination and its interpretation. Comparison with prior relevant imaging studies may prove helpful. Images of all appropriate areas, both normal and abnormal, should be recorded. Variations from normal size should generally be accompanied by measurements. Images should be labeled with the patient identification, facility identification, examination date, image orientation, and anatomic structure recorded. An official interpretation (final report) of the ultrasound examination should be included in the patient's medical record. Retention of the ultrasound examination images should be consistent both with clinical need and with relevant legal and local health care facility requirements [95].

## VI. EQUIPMENT SPECIFICATIONS

Equipment performance monitoring should be in accordance with the [ACR–AAPM Technical Standard for Diagnostic Medical Physics Performance Monitoring of Real Time Ultrasound Equipment \[15\]](#).

Obstetrical ultrasound examinations should be conducted with modern imaging systems, using a transabdominal and/or transvaginal approach. The choice of transducer frequency is a tradeoff between beam penetration and resolution. In most patients, an abdominal transducer of =3 MHz allows sufficient penetration while providing adequate resolution. During early pregnancy, transvaginal ultrasound may provide superior resolution while still allowing adequate penetration.

## VII. QUALITY CONTROL AND IMPROVEMENT, SAFETY, INFECTION CONTROL, AND PATIENT EDUCATION

Policies and procedures related to quality, patient education, infection control, and safety should be developed and implemented in accordance with the ACR Policy on Quality Control and Improvement, Safety, Infection Control, and Patient Education appearing under the heading *Position Statement on QC & Improvement, Safety, Infection Control, and Patient Education* on the ACR website (<https://www.acr.org/Advocacy-and-Economics/ACR-Position-Statements/Quality-Control-and-Improvement>).

All probes should be cleaned after use. Vaginal probes should be covered by a protective sheath prior to insertion.

Following the examination, the sheath should be disposed of and the probe cleaned with a high-level disinfectant according to the manufacturer and local infectious disease recommendation.

#### Fetal Safety

Diagnostic ultrasound studies of the embryo/fetus are generally considered to be safe during pregnancy [1,2,112-115]. This diagnostic procedure should be performed only when there is a valid medical indication, and the lowest possible acoustic output setting should be used to gain the necessary diagnostic information under the "as low as reasonably achievable" (ALARA) principle [1-3,6,112-115].

A thermal index for soft tissue (TIs) should be used at <10 weeks' gestation and a thermal index for bone should be used at =10 weeks' gestation when bone ossification is evident [3,116]. A TI ratio of 0.7 or less should be used for obstetrical scanning. Higher acoustic outputs should only be used if needed to obtain diagnostic quality images. In keeping with the ALARA principle, spectral Doppler ultrasound should not be used unless clinically indicated [6,101].

The promotion, selling, or leasing of ultrasound equipment for making "keepsake fetal videos" is considered by the U.S. Food and Drug Administration (FDA) to be an unapproved use of a medical device [117-119]. Use of a diagnostic ultrasound system for these purposes, without a physician's order, may be in violation of state laws or regulations [102].

#### ACKNOWLEDGEMENTS

This practice parameter was revised according to the process described under the heading *The Process for Developing ACR Practice Parameters and Technical Standards* on the ACR website (<https://www.acr.org/Clinical-Resources/Practice-Parameters-and-Technical-Standards>) by the Committee on Practice Parameters – Ultrasound of the ACR Commission on Ultrasound, in collaboration with the AIUM, the ACOG, the SMFM, and the SRU.

Writing Committee - members represent their societies in the initial and final revision of this practice parameter

#### ACR

Marcela Böhm-Velez, MD, FACR, Chair

Anne M. Kennedy, MBChB

Roya Sohaey, MD

#### ACOG

Lynn Simpson, MD

#### AIUM

Timothy Canavan, MD

Mishella Perez BS, RDMS, RDCS, FAIUM

Lorraine Toner, MD

#### SRU

Rochelle F. Andreotti, MD, FACR, FSRU, FAIUM

Nadia J. Khati, MD, FACR

#### SMFM

Tracy Anton BS, RDMS, RDCS, FAIUM

Lorraine Dugoff, MD

Christina Han, MD

Juliana Martins, MD

Committee on Practice Parameters – Ultrasound

(ACR Committee responsible for sponsoring the draft through the process)

Nirvikar Dahiya, MD, FAIUM, FSRU, Chair

Michelle L Melany, MD, FACR

Osama Ali, MD

Harriet J. Paltiel, MD

Marcela Böhm-Velez, MD, FACR

Rupinder Penna, MD

Baljot S. Chahal, MD, MBA, BSc

Kristin L. Rebik, DO

Christopher Fung, MD

Henrietta K. Rosenberg, MD, FACR

Helena Gabriel, MD

Judy H. Squires, MD

Jamie Hui, MD

Joel P. Thompson, MD

Stephen I. Johnson, MD

Lauren P. Nicola, MD, Chair, Commission on Ultrasound

David B. Larson, MD, MBA, FACR, Chair, Commission on Quality and Safety

Mary S. Newell, MD, FACR, Chair, Committee on Practice Parameters and Technical Standards

Comments Reconciliation Committee

Rachel Gerson, MD -CSC Chair

Nadia J. Khati, MD, FACR

Dan Rodgers, MD-CSC Co-Chair

Amy L. Kotsenas, MD, FACR

Rochelle F. Andreotti, MD, FACR, FSRU, FAIUM

David A. Larson, MD

Marcela Böhm-Velez, MD, FACR

Terry L. Levin, MD, FACR

## Comments Reconciliation Committee

Bryann Bromley, MD	Juliana Martins, MD
Timothy Canavan, MD	Mary S. Newell, MD, FACR
Timothy A. Crummy, MD, MHA, FACR	Lauren Nicola, MD
Nirvikar Dahiya, MD, FAIUM, FSRU	Mishella Perez BS, RDMS, RDCS, FAIUM
Lorraine Dugoff, MD	Jim Schwayder, MD
Christina Han, MD	Lynn Simpson, MD
Tracy Hanton, MD	Roya Sohaey, MD
Anne M. Kennedy, MBChB	Lorraine Toner, MD

## **REFERNCES**

1. Barnett SB, Ter Haar GR, Ziskin MC, Rott HD, Duck FA, Maeda K. International recommendations and guidelines for the safe use of diagnostic ultrasound in medicine. *Ultrasound in medicine & biology* 2000;26:355-66.
2. American institute of Ultrasound in Medicine. *Medical Ultrasound Safety, Fourth Edition*. 4th ed; 2020.
3. American Institute of Ultrasound in Medicine. Recommended Maximum Scanning Times for Displayed Thermal Index (TI) Values. Available at: <http://www.aium.org/officialStatements/65> Accessed August 28, 2022.
4. American Institute of Ultrasound in Medicine. AIUM Practice Parameter for the Performance of Detailed Second- and Third-Trimester Diagnostic Obstetric Ultrasound Examinations. *Journal of ultrasound in medicine : official journal of the American Institute of Ultrasound in Medicine* 2019;38:3093-100.
5. Hill MA. Embryology Carnegie Stage 23. Available at: [https://embryology.med.unsw.edu.au/embryology/index.php/Carnegie\\_stage\\_23](https://embryology.med.unsw.edu.au/embryology/index.php/Carnegie_stage_23). Accessed August 28, 2022.
6. American Institute of Ultrasound in Medicine. Prudent Use and Safety of Diagnostic Ultrasound in Pregnancy. Available at: [https://www.aium.org/officialStatements/79?\\_\\_sw\\_csrfToken=0feeafcb](https://www.aium.org/officialStatements/79?__sw_csrfToken=0feeafcb). Accessed August 28, 2022.
7. American institute of Ultrasound in Medicine. Limited Obstetrical Ultrasound Examination. Available at: [https://www.aium.org/officialStatements/19?\\_\\_sw\\_csrfToken=0feeafcb](https://www.aium.org/officialStatements/19?__sw_csrfToken=0feeafcb). Accessed August 28, 2022.
8. International Society of Ultrasound in O, Gynecology, Carvalho JS, et al. ISUOG Practice Guidelines (updated): sonographic screening examination of the fetal heart. *Ultrasound in obstetrics & gynecology : the official journal of the International Society of Ultrasound in Obstetrics and Gynecology* 2013;41:348-59.
9. Perinatal Quality Foundation. Nuchal Translucency Quality Review. Available at: <https://ntqr.perinatalquality.org/>. Accessed August 28, 2022.
10. Fetal Medicine Foundation. Certificates of Competence - Nuchal Translucency Scan. Available at: <https://fetalmedicine.org/fmf-certification-2/nuchal-translucency-scan>. Accessed August 28, 2022.
11. Fetal Medicine Foundation. Cervical Assessment. Available at: <https://fetalmedicine.org/> Accessed August 28, 2022.

12. Perinatal Quality Foundation. Clear Length Education and Review. Available at: <https://clear.perinatalquality.org/> Accessed August 28, 2022.
13. Reicher L, Fouks Y, Yogev Y. Cervical Assessment for Predicting Preterm Birth-Cervical Length and Beyond. *Journal of clinical medicine* 2021;10.
14. American Institute of Ultrasound in Medicine. AIUM Practice Parameter for the Performance of Fetal Echocardiography. *Journal of ultrasound in medicine : official journal of the American Institute of Ultrasound in Medicine* 2020;39:E5-E16.
15. American College of Radiology. ACR-AAPM Technical Standard for Diagnostic Medical Physics Performance Monitoring of Real Time Ultrasound Equipment. Available at: <https://www.acr.org/-/media/ACR/Files/Practice-Parameters/US-Equip.pdf>. Accessed February 7, 2022.
16. Barnhart K, van Mello NM, Bourne T, et al. Pregnancy of unknown location: a consensus statement of nomenclature, definitions, and outcome. *Fertility and sterility* 2011;95:857-66.
17. Doubilet PM, Benson CB. Ultrasound of the Early First Trimester. *Callen's Ultrasonography in Obstetrics and Gynecology*. 6 ed; 2017.
18. Wang PS, Rodgers SK, Horrow MM. Ultrasound of the First Trimester. *Radiologic clinics of North America* 2019;57:617-33.
19. Abdallah Y, Daemen A, Kirk E, et al. Limitations of current definitions of miscarriage using mean gestational sac diameter and crown-rump length measurements: a multicenter observational study. *Ultrasound in obstetrics & gynecology : the official journal of the International Society of Ultrasound in Obstetrics and Gynecology* 2011;38:497-502.
20. Doubilet PM, Benson CB. First, do no harm... To early pregnancies. *Journal of ultrasound in medicine : official journal of the American Institute of Ultrasound in Medicine* 2010;29:685-9.
21. Doubilet PM, Benson CB, Bourne T, et al. Diagnostic criteria for nonviable pregnancy early in the first trimester. *The New England journal of medicine* 2013;369:1443-51.
22. Jevc Y, Rana R, Bhide A, Thangaratinam S. Accuracy of first-trimester ultrasound in the diagnosis of early embryonic demise: a systematic review. *Ultrasound in obstetrics & gynecology : the official journal of the International Society of Ultrasound in Obstetrics and Gynecology* 2011;38:489-96.
23. Thilaganathan B. The evidence base for miscarriage diagnosis: better late than never. *Ultrasound in obstetrics & gynecology : the official journal of the International Society of Ultrasound in Obstetrics and Gynecology* 2011;38:487-8.
24. Papageorghiou AT, Kennedy SH, Salomon LJ, et al. International standards for early fetal size and pregnancy dating based on ultrasound measurement of crown-rump length in the first trimester of pregnancy. *Ultrasound in obstetrics & gynecology : the official journal of the International Society of Ultrasound in Obstetrics and Gynecology* 2014;44:641-8.
25. Ioannou C, Sarris I, Hoch L, et al. Standardisation of crown-rump length measurement. *BJOG* 2013;120 Suppl 2:38-41, v.
26. Napolitano R, Dhama J, Ohuma EO, et al. Pregnancy dating by fetal crown-rump length: a systematic review of charts. *BJOG* 2014;121:556-65.
27. Maruotti GM, Saccone G, Morlando M, Martinelli P. First-trimester ultrasound determination of chorionicity in twin gestations using the lambda sign: a systematic review and meta-analysis. *European journal of obstetrics, gynecology, and reproductive biology* 2016;202:66-70.
28. Jha P, Morgan TA, Kennedy A. US Evaluation of Twin Pregnancies: Importance of Chorionicity and Amnionity. *Radiographics : a review publication of the Radiological Society of North America, Inc* 2019;39:2146-66.
29. Frates MC, Doubilet PM, Peters HE, Benson CB. Adnexal sonographic findings in ectopic pregnancy and their correlation with tubal rupture and human chorionic gonadotropin levels. *Journal of ultrasound in medicine : official journal of the American Institute of Ultrasound in Medicine* 2014;33:697-703.
30. Nadim B, Infante F, Lu C, Sathasivam N, Condous G. The morphological ultrasound types known as 'blob' and 'bagel' signs should be reclassified from probable to definite ectopic pregnancy. *Ultrasound in obstetrics & gynecology : the official journal of the International Society of Ultrasound in Obstetrics and Gynecology* 2017.
31. Jauniaux E, Memtsa M, Johns J, Ross JA, Sebire NJ, Jurkovic D. Ultrasound diagnosis of complete and partial hydatidiform moles in early pregnancy failure: An inter-observer study. *Placenta* 2020;97:65-67.
32. Rossi AC, Prefumo F. Accuracy of ultrasonography at 11-14 weeks of gestation for detection of fetal

- structural anomalies: a systematic review. *Obstetrics and gynecology* 2013;122:1160-7.
33. Syngelaki A, Chelemen T, Dagklis T, Allan L, Nicolaides KH. Challenges in the diagnosis of fetal non-chromosomal abnormalities at 11-13 weeks. *Prenatal diagnosis* 2011;31:90-102.
  34. Souka AP, Pilalis A, Kavalakis I, et al. Screening for major structural abnormalities at the 11- to 14-week ultrasound scan. *American journal of obstetrics and gynecology* 2006;194:393-6.
  35. Bromley B, Shipp TD, Lyons J, Navathe RS, Groszmann Y, Benacerraf BR. Detection of fetal structural anomalies in a basic first-trimester screening program for aneuploidy. *Journal of ultrasound in medicine : official journal of the American Institute of Ultrasound in Medicine* 2014;33:1737-45.
  36. Harper LM, Wood SL, Jenkins SM, Owen J, Biggio JR. The Performance of First-Trimester Anatomy Scan: A Decision Analysis. *Am J Perinatol* 2016;33:957-65.
  37. Liao Y, Wen H, Ouyang S, et al. Routine first-trimester ultrasound screening using a standardized anatomical protocol. *American journal of obstetrics and gynecology* 2021;224:396.e1-96.e15.
  38. Turan S, Goetzinger KR. First-trimester fetal heart evaluation: time to move forward. *Ultrasound in Obstetrics & Gynecology* 2021;57:677-80.
  39. Malone FD, Canick JA, Ball RH, et al. First-trimester or second-trimester screening, or both, for Down's syndrome. *The New England journal of medicine* 2005;353:2001-11.
  40. Santorum M, Wright D, Syngelaki A, Karagioti N, Nicolaides KH. Accuracy of first trimester combined test in screening for trisomies 21, 18 and 13. *Ultrasound in obstetrics & gynecology : the official journal of the International Society of Ultrasound in Obstetrics and Gynecology* 2016.
  41. Gadsbøll K, Wright A, Kristensen SE, et al. Crown-rump length measurement error: impact on assessment of growth. *Ultrasound in obstetrics & gynecology : the official journal of the International Society of Ultrasound in Obstetrics and Gynecology* 2021;58:354-59.
  42. Salomon LJ, Alfirevic Z, Bilardo CM, et al. ISUOG practice guidelines: performance of first-trimester fetal ultrasound scan. *Ultrasound in obstetrics & gynecology : the official journal of the International Society of Ultrasound in Obstetrics and Gynecology* 2013;41:102-13.
  43. Volpe N, Sen C, Turan S, et al. First trimester examination of fetal anatomy: clinical practice guideline by the World Association of Perinatal Medicine (WAPM) and the Perinatal Medicine Foundation (PMF). *Journal of perinatal medicine* 2022.
  44. Medicine AIoUi. AIUM Practice Parameter for the Performance of Detailed Diagnostic Obstetric Ultrasound Examinations Between 12 Weeks 0 Days and 13 Weeks 6 Days. *Journal of ultrasound in medicine : official journal of the American Institute of Ultrasound in Medicine* 2021;40:E1-E16.
  45. Whitworth M, Bricker L, Mullan C. Ultrasound for fetal assessment in early pregnancy. *Cochrane Database Syst Rev* 2015:CD007058.
  46. Grandjean H, Larroque D, Levi S. The performance of routine ultrasonographic screening of pregnancies in the Eurofetus Study. *American journal of obstetrics and gynecology* 1999;181:446-54.
  47. Saltvedt S, Almstrom H, Kublickas M, Valentin L, Grunewald C. Detection of malformations in chromosomally normal fetuses by routine ultrasound at 12 or 18 weeks of gestation-a randomised controlled trial in 39,572 pregnancies. *BJOG* 2006;113:664-74.
  48. Westin M, Saltvedt S, Bergman G, et al. Routine ultrasound examination at 12 or 18 gestational weeks for prenatal detection of major congenital heart malformations? A randomised controlled trial comprising 36,299 fetuses. *BJOG* 2006;113:675-82.
  49. Pilalis A, Basagiannis C, Eleftheriades M, et al. Evaluation of a two-step ultrasound examination protocol for the detection of major fetal structural defects. *J Matern Fetal Neonatal Med* 2012;25:1814-7.
  50. Wong J, Kohari K, Bahtiyar MO, Copel J. Impact of prenatally diagnosed congenital heart defects on outcomes and management. *Journal of clinical ultrasound : JCU* 2022;50:646-54.
  51. Liu H, Zhou J, Feng QL, et al. Fetal echocardiography for congenital heart disease diagnosis: a meta-analysis, power analysis and missing data analysis. *Eur J Prev Cardiol* 2015;22:1531-47.
  52. Offerdal K, Jebens N, Syvertsen T, Blaas HG, Johansen OJ, Eik-Nes SH. Prenatal ultrasound detection of facial clefts: a prospective study of 49,314 deliveries in a non-selected population in Norway. *Ultrasound in obstetrics & gynecology : the official journal of the International Society of Ultrasound in Obstetrics and Gynecology* 2008;31:639-46.
  53. Mahan ST, Yazdy MM, Kasser JR, Werler MM. Prenatal screening for clubfoot: what factors predict prenatal detection? *Prenatal diagnosis* 2014;34:389-93.
  54. Nguyen HT, Benson CB, Bromley B, et al. Multidisciplinary consensus on the classification of prenatal and

- postnatal urinary tract dilation (UTD classification system). *J Pediatr Urol* 2014;10:982-98.
55. Gardiner H, Chaoui R. The fetal three-vessel and tracheal view revisited. *Semin Fetal Neonatal Med* 2013;18:261-8.
  56. Yagel S, Arbel R, Anteby EY, Raveh D, Achiron R. The three vessels and trachea view (3VT) in fetal cardiac scanning. *Ultrasound in obstetrics & gynecology : the official journal of the International Society of Ultrasound in Obstetrics and Gynecology* 2002;20:340-5.
  57. Vinals F, Heredia F, Giuliano A. The role of the three vessels and trachea view (3VT) in the diagnosis of congenital heart defects. *Ultrasound in obstetrics & gynecology : the official journal of the International Society of Ultrasound in Obstetrics and Gynecology* 2003;22:358-67.
  58. Vinals F, Ascenzo R, Poblete P, Comas C, Vargas G, Giuliano A. Simple approach to prenatal diagnosis of transposition of the great arteries. *Ultrasound in obstetrics & gynecology : the official journal of the International Society of Ultrasound in Obstetrics and Gynecology* 2006;28:22-5.
  59. McGahan JP, Moon-Grady AJ, Pahwa A, et al. Potential pitfalls and methods of improving in utero diagnosis of transposition of the great arteries, including the baby bird's beak image. *Journal of ultrasound in medicine : official journal of the American Institute of Ultrasound in Medicine* 2007;26:1499-510; quiz 511.
  60. Tongsong T, Tongprasert F, Srisupundit K, Luewan S. The complete three-vessel view in prenatal detection of congenital heart defects. *Prenatal diagnosis* 2010;30:23-9.
  61. Crane JM, Hutchens D. Transvaginal sonographic measurement of cervical length to predict preterm birth in asymptomatic women at increased risk: a systematic review. *Ultrasound in obstetrics & gynecology : the official journal of the International Society of Ultrasound in Obstetrics and Gynecology* 2008;31:579-87.
  62. Son M, Grobman WA, Ayala NK, Miller ES. A universal mid-trimester transvaginal cervical length screening program and its associated reduced preterm birth rate. *American journal of obstetrics and gynecology* 2016;214:365 e1-5.
  63. Iams JD, Grobman WA, Lozitska A, et al. Adherence to criteria for transvaginal ultrasound imaging and measurement of cervical length. *American journal of obstetrics and gynecology* 2013;209:365 e1-5.
  64. Romero R, Nicolaides KH, Conde-Agudelo A, et al. Vaginal progesterone decreases preterm birth. *Obstetrics and gynecology* 2016;48:308-17.
  65. Berghella V, Palacio M, Ness A, Alfirevic Z, Nicolaides KH, Saccone G. Cervical length screening for prevention of preterm birth in singleton pregnancy with threatened preterm labor: systematic review and meta-analysis of randomized controlled trials using individual patient-level data. *Ultrasound in obstetrics & gynecology : the official journal of the International Society of Ultrasound in Obstetrics and Gynecology* 2017;49:322-29.
  66. Kiserud T, Piaggio G, Carroli G, et al. The World Health Organization Fetal Growth Charts: A Multinational Longitudinal Study of Ultrasound Biometric Measurements and Estimated Fetal Weight. *PLoS Med* 2017;14:e1002220.
  67. Papageorgiou AT, Ohuma EO, Altman DG, et al. International standards for fetal growth based on serial ultrasound measurements: the Fetal Growth Longitudinal Study of the INTERGROWTH-21st Project. *Lancet* 2014;384:869-79.
  68. Buck Louis GM, Grewal J, Albert PS, et al. Racial/ethnic standards for fetal growth: the NICHD Fetal Growth Studies. *American journal of obstetrics and gynecology* 2015;213:449 e1-49 e41.
  69. Stirnemann J, Villar J, Salomon LJ, et al. International estimated fetal weight standards of the INTERGROWTH-21st Project. *Ultrasound in obstetrics & gynecology : the official journal of the International Society of Ultrasound in Obstetrics and Gynecology* 2017;49:478-86.
  70. Magann EF, Sanderson M, Martin JN, Chauhan S. The amniotic fluid index, single deepest pocket, and two-diameter pocket in normal human pregnancy. *American journal of obstetrics and gynecology* 2000;182:1581-8.
  71. Kehl S, Schelkle A, Thomas A, et al. Single deepest vertical pocket or amniotic fluid index as evaluation test for predicting adverse pregnancy outcome (SAFE trial): a multicenter, open-label, randomized controlled trial. *Ultrasound in obstetrics & gynecology : the official journal of the International Society of Ultrasound in Obstetrics and Gynecology* 2016;47:674-9.
  72. Reddy UM, Abuhamad AZ, Levine D, Saade GR, Fetal Imaging Workshop Invited P. Fetal imaging: Executive summary of a Joint Eunice Kennedy Shriver National Institute of Child Health and Human Development, Society for Maternal-Fetal Medicine, American Institute of Ultrasound in Medicine, American College of Obstetricians and Gynecologists, American College of Radiology, Society for Pediatric Radiology, and Society



- of Radiologists in Ultrasound Fetal Imaging Workshop. American journal of obstetrics and gynecology 2014;210:387-97.
73. Byrne JJ, Morgan JL, Twickler DM, McIntire DD, Dashe JS. Utility of follow-up standard sonography for fetal anomaly detection. American journal of obstetrics and gynecology 2020;222:615.e1-15.e9.
  74. Shainker SA, Coleman B, Timor-Tritsch IE, et al. Special Report of the Society for Maternal-Fetal Medicine Placenta Accreta Spectrum Ultrasound Marker Task Force: Consensus on definition of markers and approach to the ultrasound examination in pregnancies at risk for placenta accreta spectrum. American journal of obstetrics and gynecology 2021;224:B2-b14.
  75. Wax J, Minkoff H, Johnson A, et al. Consensus report on the detailed fetal anatomic ultrasound examination: indications, components, and qualifications. Journal of ultrasound in medicine : official journal of the American Institute of Ultrasound in Medicine 2014;33:189-95.
  76. Nabhan AF, Abdelmoula YA. Amniotic fluid index versus single deepest vertical pocket as a screening test for preventing adverse pregnancy outcome. Cochrane Database Syst Rev 2008:CD006593.
  77. Hughes DS, Magann EF, Whittington JR, Wendel MP, Sandlin AT, Ounpraseuth ST. Accuracy of the Ultrasound Estimate of the Amniotic Fluid Volume (Amniotic Fluid Index and Single Deepest Pocket) to Identify Actual Low, Normal, and High Amniotic Fluid Volumes as Determined by Quantile Regression. Journal of ultrasound in medicine : official journal of the American Institute of Ultrasound in Medicine 2020;39:373-78.
  78. Pretorius DH, Chau C, Poeltler DM, Mendoza A, Catanzarite VA, Hollenbach KA. Placental cord insertion visualization with prenatal ultrasonography. Journal of ultrasound in medicine : official journal of the American Institute of Ultrasound in Medicine 1996;15:585-93.
  79. Sepulveda W, Rojas I, Robert JA, Schnapp C, Alcalde JL. Prenatal detection of velamentous insertion of the umbilical cord: a prospective color Doppler ultrasound study. Ultrasound in obstetrics & gynecology : the official journal of the International Society of Ultrasound in Obstetrics and Gynecology 2003;21:564-9.
  80. Society of Maternal-Fetal Publications C, Sinkey RG, Odibo AO, Dashe JS. #37: Diagnosis and management of vasa previa. American journal of obstetrics and gynecology 2015;213:615-9.
  81. Swank ML, Garite TJ, Maurel K, et al. Vasa previa: diagnosis and management. American journal of obstetrics and gynecology 2016;215:223 e1-6.
  82. Vintzileos AM, Ananth CV, Smulian JC. Using ultrasound in the clinical management of placental implantation abnormalities. American journal of obstetrics and gynecology 2015;213:S70-S77.
  83. Pavalagantharajah S, Villani LA, D'Souza R. Vasa previa and associated risk factors: a systematic review and meta-analysis. Am J Obstet Gynecol MFM 2020;2:100117.
  84. Ruitter L, Kok N, Limpens J, et al. Systematic review of accuracy of ultrasound in the diagnosis of vasa previa. Ultrasound in obstetrics & gynecology : the official journal of the International Society of Ultrasound in Obstetrics and Gynecology 2015;45:516-22.
  85. Benson CB, Doubilet PM. Sonographic prediction of gestational age: accuracy of second- and third-trimester fetal measurements. AJR. American journal of roentgenology 1991;157:1275-7.
  86. Butt K, Lim K, Diagnostic Imaging C. Determination of gestational age by ultrasound. Journal of obstetrics and gynaecology Canada : JOGC = Journal d'obstetrique et gynecologie du Canada : JOGC 2014;36:171-81.
  87. Committee on Obstetric Practice: ACOG/AIUM/SMFM. Committee Opinion No 700: Methods for Estimating the Due Date. Obstetrics and gynecology 2017;129:e150-e54.
  88. American College of Obstetricians and Gynecologists. Management of Suboptimally Dated Pregnancies. Number 688:Available at: <https://www.acog.org/clinical/clinical-guidance/committee-opinion/articles/2017/03/management-of-suboptimally-dated-pregnancies>. Accessed April 18, 2017.
  89. American College of Obstetricians and Gynecologists. Method of Estimating Due Date. Number 611:Available at: <https://www.acog.org/clinical/clinical-guidance/committee-opinion/articles/2017/05/methods-for-estimating-the-due-date>. Accessed August 28, 2022.
  90. Callen PW, Callen AL, Glenn OA, Toi A. Columns of the Fornix, Not to Be Mistaken for the Cavum Septi Pellucidi on Prenatal Sonography. Journal of Ultrasound in Medicine 2008;27:25-31.
  91. Hadlock FP, Harrist RB, Sharman RS, Deter RL, Park SK. Estimation of fetal weight with the use of head, body, and femur measurements--a prospective study. American journal of obstetrics and gynecology 1985;151:333-7.
  92. Hadlock FP, Harrist RB, Carpenter RJ, Deter RL, Park SK. Sonographic estimation of fetal weight. The value of femur length in addition to head and abdomen measurements. Radiology 1984;150:535-40.

93. Kiserud T, Piaggio G, Carroli G, et al. Correction: The World Health Organization Fetal Growth Charts: A Multinational Longitudinal Study of Ultrasound Biometric Measurements and Estimated Fetal Weight. *PLoS Med* 2017;14:e1002284.
94. Hadlock FP, Harrist RB, Martinez-Poyer J. In utero analysis of fetal growth: a sonographic weight standard. *Radiology* 1991;181:129-33.
95. Grantz KL. Fetal Growth Curves: Is There a Universal Reference? *Obstetrics and gynecology clinics of North America* 2021;48:281-96.
96. Deter RL, Harrist RB. Growth standards for anatomic measurements and growth rates derived from longitudinal studies of normal fetal growth. *Journal of clinical ultrasound : JCU* 1992;20:381-8.
97. Mongelli M, Ek S, Tambyrajia R. Screening for fetal growth restriction: a mathematical model of the effect of time interval and ultrasound error. *Obstetrics and gynecology* 1998;92:908-12.
98. Narang K, Novoa VAN, Alrahmani L, et al. Management of Complicated Monochorionic Twin Gestations: An Evidence-Based Protocol. *Obstetrical & gynecological survey* 2021;76:541-49.
99. Hoskins IA, Combs CA. Society for Maternal-Fetal Medicine Special Statement: Updated checklists for management of monochorionic twin pregnancy. *American journal of obstetrics and gynecology* 2020;223:B16-b20.
100. Benson CB, Doubilet PM. Fetal Biometry and Growth. In: Elsevier, ed. *Callen's Ultrasonography in Obstetrics and Gynecology*. 6th ed. Philadelphia. ; 2016.
101. Friedman AM, Srinivas SK, Parry S, Elovitz MA, Wang E, Schwartz N. Can transabdominal ultrasound be used as a screening test for short cervical length? *American journal of obstetrics and gynecology* 2013;208:190.e1-7.
102. Pasko DN, Wood SL, Jenkins SM, Owen J, Harper LM. Completion and Sensitivity of the Second-Trimester Fetal Anatomic Survey in Obese Gravida. *Journal of ultrasound in medicine : official journal of the American Institute of Ultrasound in Medicine* 2016;35:2449-57.
103. Thornburg LL, Miles K, Ho M, Pressman EK. Fetal anatomic evaluation in the overweight and obese gravida. *Ultrasound in obstetrics & gynecology : the official journal of the International Society of Ultrasound in Obstetrics and Gynecology* 2009;33:670-5.
104. Dashe JS, McIntire DD, Twickler DM. Effect of maternal obesity on the ultrasound detection of anomalous fetuses. *Obstetrics and gynecology* 2009;113:1001-7.
105. Dashe JS, McIntire DD, Twickler DM. Maternal obesity limits the ultrasound evaluation of fetal anatomy. *Journal of ultrasound in medicine : official journal of the American Institute of Ultrasound in Medicine* 2009;28:1025-30.
106. Benacerraf B. The significance of the nuchal fold in the second trimester fetus. *Prenatal diagnosis* 2002;22:798-801.
107. Tegnander E, Williams W, Johansen OJ, Blaas HGK, Eik-Nes SH. Prenatal detection of heart defects in a non-selected population of 30 149 fetuses—detection rates and outcome. *Ultrasound in Obstetrics & Gynecology* 2006;27:252-65.
108. Marinac-Dabic D, Krulewitch CJ, Moore RM, Jr. The safety of prenatal ultrasound exposure in human studies. *Epidemiology* 2002;13 Suppl 3:S19-22.
109. American Institute of Ultrasound in Medicine. Conclusions Regarding Epidemiology for Obstetric Ultrasound. Available at: <http://www.aium.org/officialStatements/16> Accessed August 28, 2022.
110. Miller MW, Brayman AA, Abramowicz JS. Obstetric ultrasonography: a biophysical consideration of patient safety--the "rules" have changed. *American journal of obstetrics and gynecology* 1998;179:241-54.
111. Sheiner E, Freeman J, Abramowicz JS. Acoustic output as measured by mechanical and thermal indices during routine obstetric ultrasound examinations. *Journal of ultrasound in medicine : official journal of the American Institute of Ultrasound in Medicine* 2005;24:1665-70.
112. Abramowicz JS. Obstetric ultrasound: where are we and where are we going? *Ultrasonography (Seoul, Korea)* 2021;40:57-74.
113. Food and Drug Administration. Fetal Keepsake Video. May 2011; <http://www.fda.gov/MedicalDevices/Safety/AlertsandNotices/PatientAlerts/ucm064756.htm>. Accessed June 11, 2012.
114. American College of Radiology. Digest of Council Actions. Available at: <https://www.acr.org/~media/ACR/Documents/PDF/Membership/Governance/Digest-of-Council-Actions.pdf?db=web> Accessed September 16, 2022.

Revised 2023 (Resolution 36), Gynecologists' Committee on Obstetric P. Committee Opinion No. 656: Guidelines for Diagnostic Imaging During Pregnancy and Lactation. Obstetrics and gynecology 2016;127:e75-80.

\*Practice parameters and technical standards are published annually with an effective date of October 1 in the year in which amended, revised or approved by the ACR Council. For practice parameters and technical standards published before 1999, the effective date was January 1 following the year in which the practice parameter or technical standard was amended, revised, or approved by the ACR Council.

Development Chronology for this Practice Parameter 1990 (Resolution 5)

Revised 1995 (Resolution 35)

Revised 1999 (Resolution 37)

Revised 2003 (Resolution 19)

Amended 2006 (Resolution 35)

Revised 2007 (Resolution 25)

Revised 2013 (Resolution 17)

Amended 2014 (Resolution 39)

Revised 2018 (Resolution 27)

Revised 2023 (Resolution 36)